

Arthroscopic Replacement of the Proximal Pole of the Scaphoid with a Pyrocarbon Implant

Chapter 20

Introduction

Avascular necrosis of the proximal pole of the scaphoid is challenging to treat. Vascularized bone grafts do not always provide the expected results. In some patients, the necrotic proximal pole is fragmented, and attempts to repair it are unrealistic. A mobile pyrocarbon implant was first implanted in 2000 through a standard open approach.¹ Inserting this implant arthroscopically is a logical next step because all the extrinsic ligaments remain intact, thereby preserving carpal bone stability. However, this technique is reserved for patients where reconstruction is impossible.

Operative Technique

Patient Preparation and Positioning

The procedure is performed under regional anesthesia with the arm secured to an arm board and upward traction of 5 to 7 kg applied to the hand, wrist, and forearm.

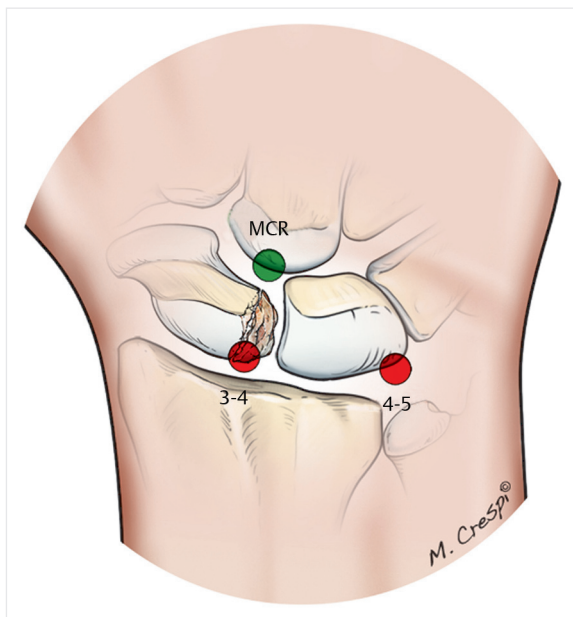


Fig. 20.1 Drawing of the three portals typically used during arthroscopic replacement of the proximal pole of the scaphoid with a pyrocarbon implant. MCR, radial midcarpal.

Arthroscopic Portals and Exploration

Three portals are generally used during this procedure (Fig. 20.1):

- Standard 3–4 portal, extended to ~1 cm to allow the implant to pass through it
- 4–5 or 6R portals for the scope
- Radial midcarpal (MCR) portal for midcarpal verification

The procedure starts with the 3–4 and 4–5 or 6R portals. The scope is inserted into the medial portal. A shaver is used to debride the joint (synovitis, bone, and/or cartilage debris). The proximal pole is located and the degree of necrosis measured (one or multiple fragments, etc.). The arthroscope and sheath are then introduced through the MCU portal to assess the proximal pole's position relative to the remainder of the scaphoid and to the lunate (Fig. 20.2a, b).

Proximal Pole Excision

All of the proximal pole's fragments will be taken out through the 3–4 portal with the scope in the radiocarpal ulnar portal. But first, the scapholunate interosseous ligament must be cut if it is still intact. A small no. 11 scalpel is used (Fig. 20.3a, b). Stevens tenotomy scissors are then used to cut through the entire scapholunate ligament (Fig. 20.4a, b). The proximal pole or its various fragments are then removed using hemostats (Fig. 20.5a–c).

If the dorsal and volar portions of the scapholunate ligament are difficult to cut, this can be accomplished with a shaver inserted in the 3–4 portal; the scope is placed into the radiocarpal ulnar portal for the dorsal portion and the MCU portal for the volar portion.

If the scaphoid's proximal end is convex, a bur is inserted through the 3–4 portal and used to reshape this end until it becomes concave and can match the implant's shape (Fig. 20.6a, b).

Selection of Implant Size

The first option for selecting the proper implant size is to reconstruct the proximal pole on the back table and then compare it with the trial implants (Fig. 20.7). The selected implant is then pushed into the 3–4 portal with the fingers under radiocarpal and midcarpal arthroscopic control

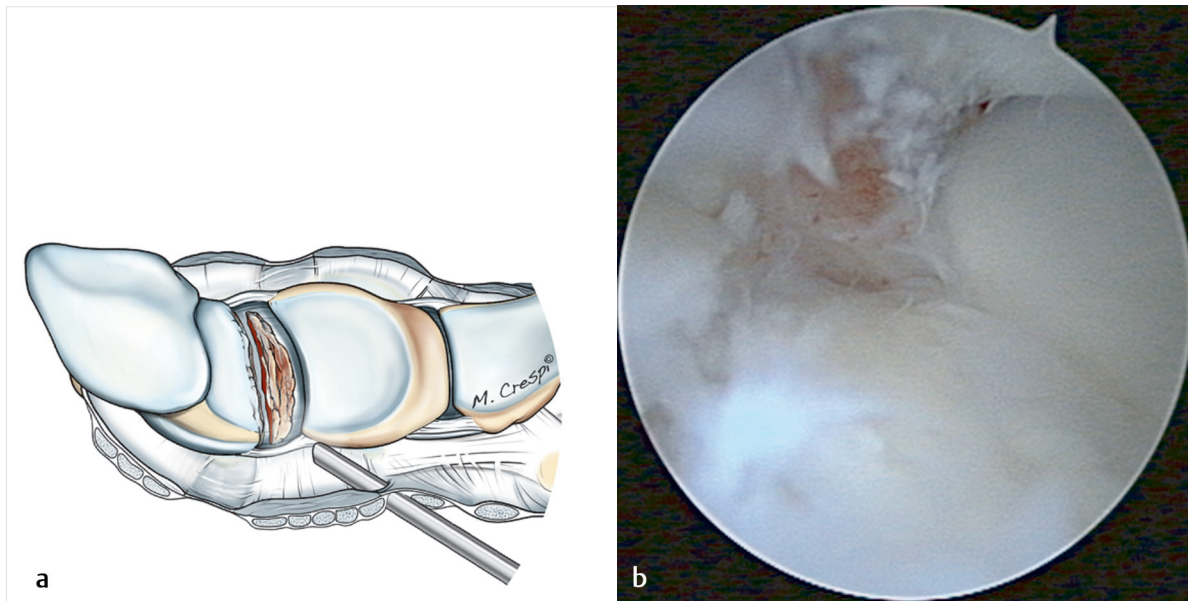


Fig. 20.2a, b Drawing (a) and midcarpal arthroscopic view (b) of the scaphoid on the left, lunate on the right, and necrotic proximal pole of the scaphoid in the middle.

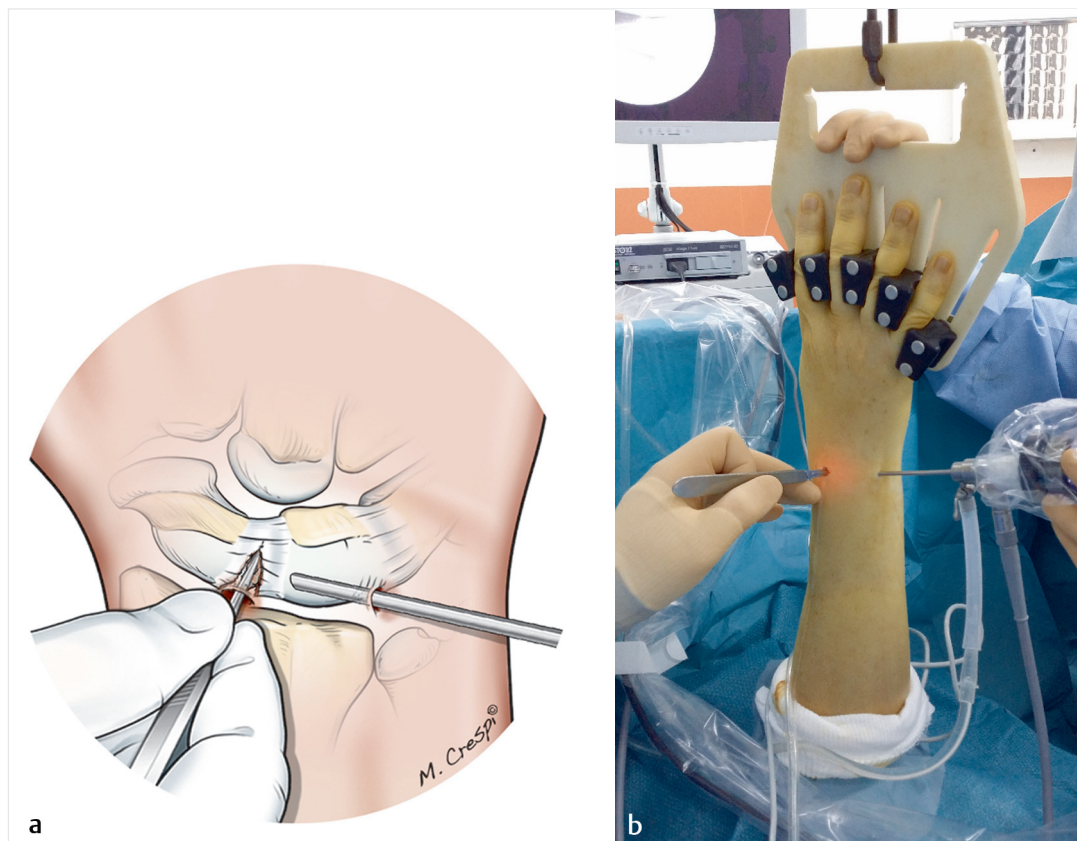


Fig. 20.3a, b Drawing (a) and intraoperative view (b) of a scalpel blade being used to start cutting the scapholunate intersosseous ligament.

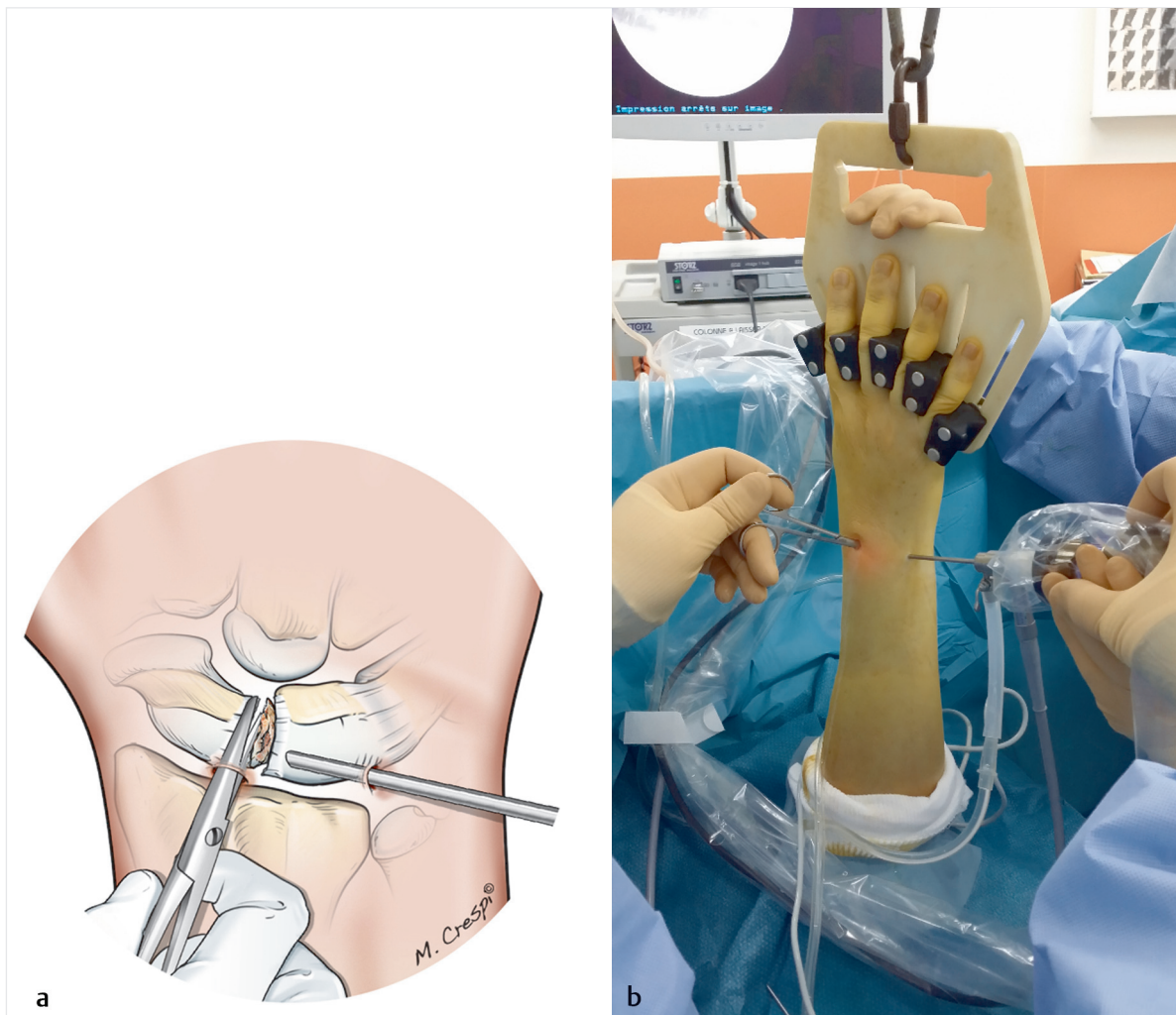


Fig. 20.4a, b Drawing (a) and intraoperative view (b) of fine tips scissors being used to make the final cut in the scapholunate interosseous ligament.

(**Fig. 20.8**). If the implant is the correct size, the midcarpal view will show that the space between the scaphoid and lunate is completely filled. A hemostat is used to remove the trial implant under radiocarpal and/or midcarpal arthroscopic control. The implant's ovoid shape can make it difficult to grasp. One trick is to place a small plastic tube (such as surgical drain tubing) on the tips of the hemostat.

Placement of the Final Implant

The final implant is inserted in the same manner (**Fig. 20.9a, b**) under dual radiocarpal and midcarpal control (**Fig. 20.10**). The skin at the extended 3–4 portal incision is closed with simple interrupted sutures. These sutures can be removed when the first dressing is changed in 1 week.

Postoperative Care

The mobile implant allows for immediate recovery of joint range of motion. Nevertheless, a removable anterior splint is used to reduce pain, while allowing patients to regain their range of motion. If needed, rehabilitation can be initiated after the third week.

Conclusion

Arthroscopic replacement of a necrotic proximal pole is a simple, reliable technique that does not burn any bridges. Long-term results with this implant are promising.² This method avoids the use of more extensive palliative methods. However, it should be used only in patients where reconstruction is impossible.

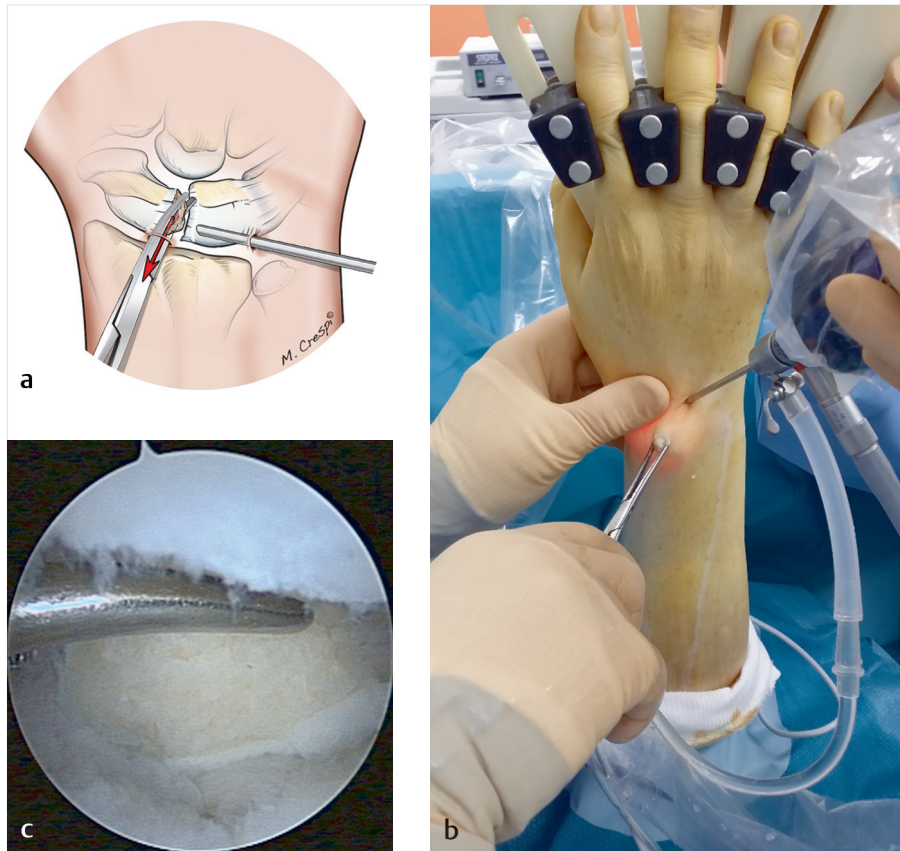

Fig. 20.5a–c Drawing (a), intraoperative view (b), and arthroscopic view (c) of the excision of necrotic fragments from the proximal pole of the scaphoid. The red arrow in (a) shows the excision of proximal pole.

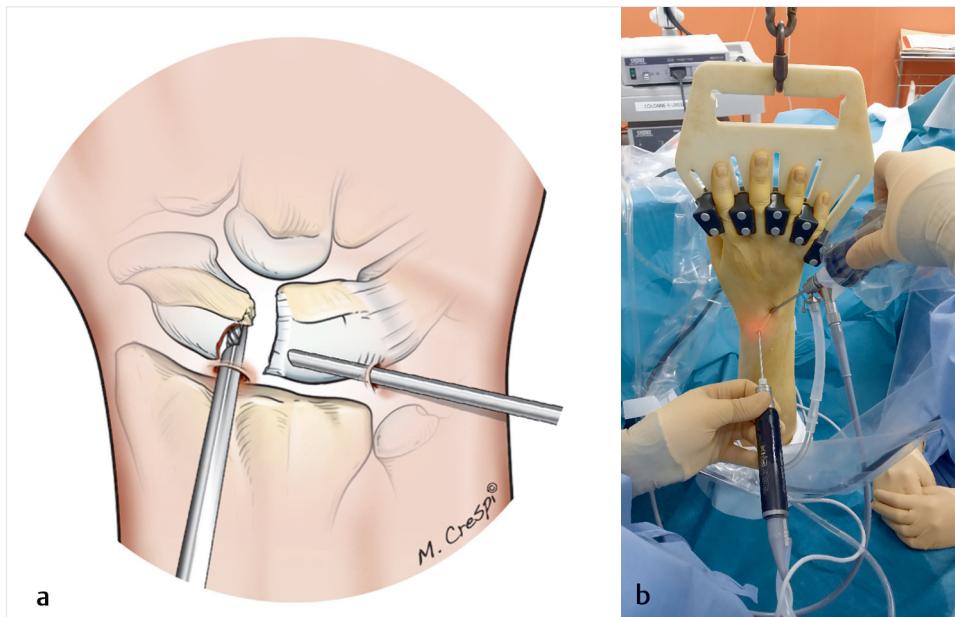


Fig. 20.6a, b Drawing (a) and intraoperative view (b) during burring of the remaining proximal end of the scaphoid.

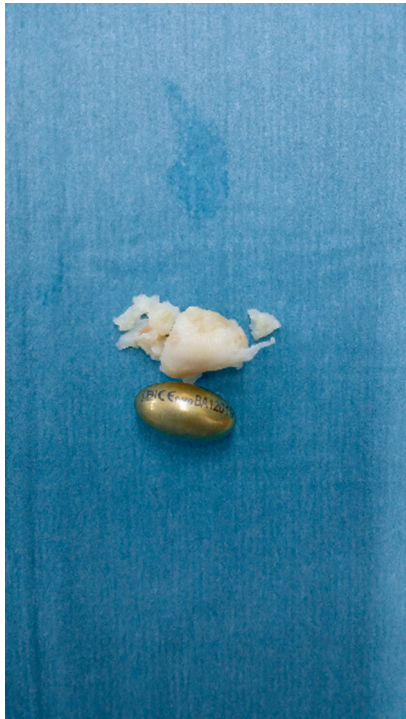


Fig. 20.7 Intraoperative view of the various fragments from the necrotic proximal pole being reconstructed on the back table to compare the fragments to the size of the trial implants.

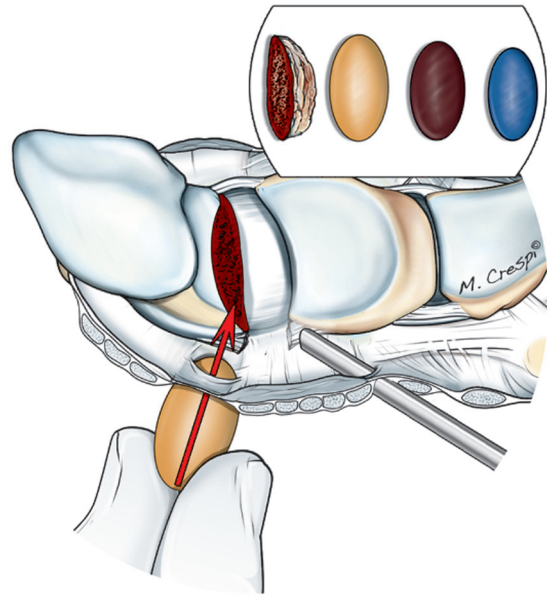
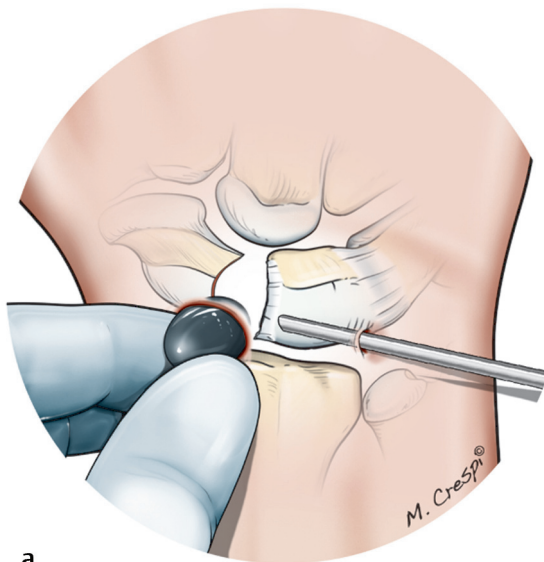
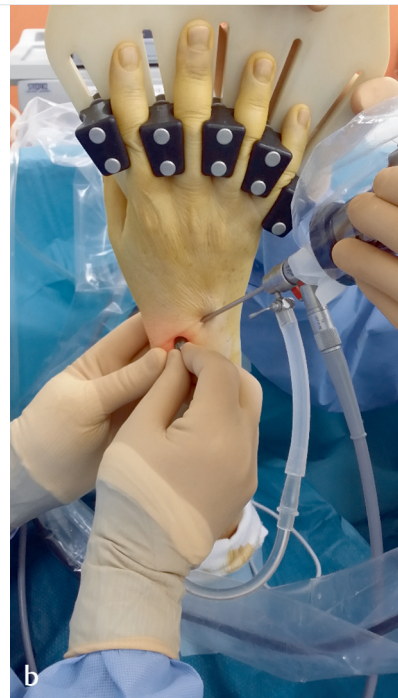

Fig. 20.8 Drawing of the trial implant being put into place.



a



b

Fig. 20.9a, b Drawing (a) and intraoperative view (b) of the final implant being inserted through an extended 3–4 radiocarpal incision.

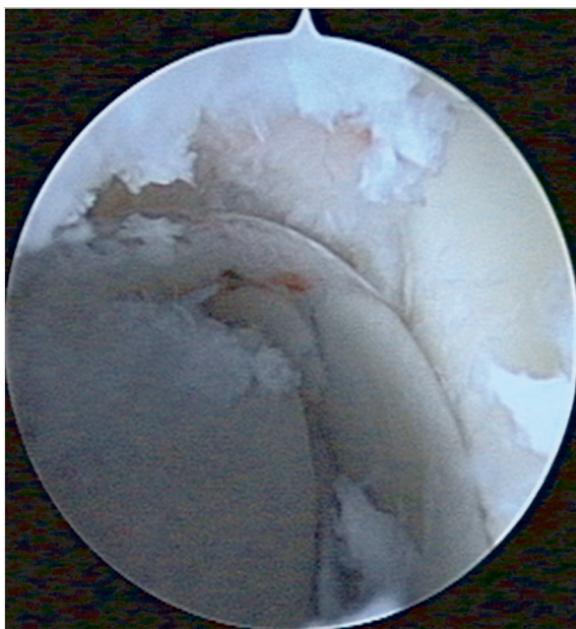


Fig. 20.10 Midcarpal arthroscopic view of the seated implant, which is perfectly positioned between the scaphoid and lunate.

References

1. Pequignot JP, Lussiez B, Allieu Y. A adaptive proximal scaphoid implant [in French]. *Chir Main* 2000;19(5):276–285
2. Gras M, Wahegaonkar AL, Mathoulin C. Treatment of avascular necrosis of the proximal pole of the scaphoid by arthroscopic resection and prosthetic semireplacement arthroplasty using the pyrocarbon adaptive proximal scaphoid implant (APSI): long-term functional outcomes. *J Wrist Surg* 2012;1(2):159–164